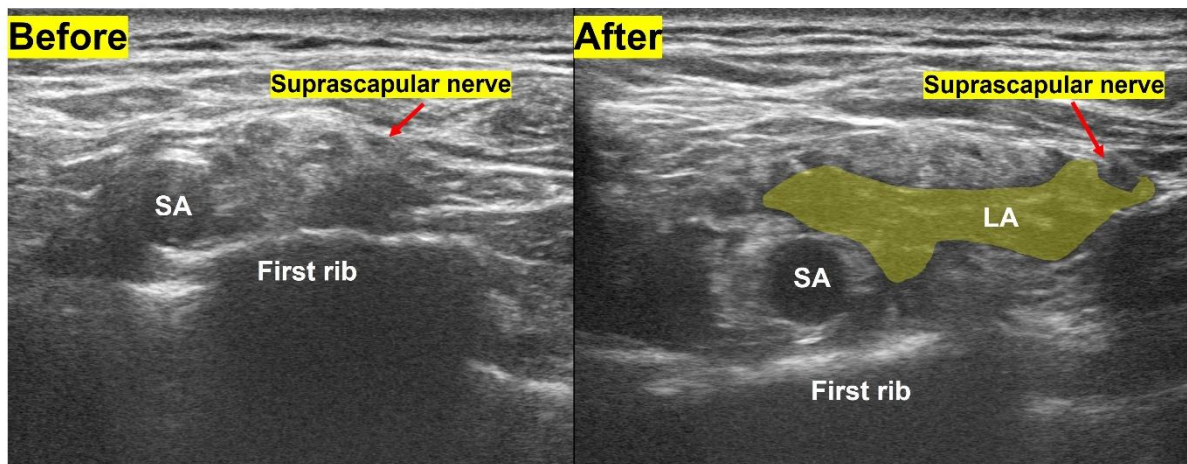


Supplementary Fig. 2. Ultrasound-guided observation of brachial plexus at the supraclavicular area. (A) Pre-block, the suprascapular nerve lies laterally within the superior trunk at the corner pocket image. (B) Local anesthetic is spread around trunks and suprascapular nerve after the costoclavicular block.



SA, subclavian artery; LA, local anesthetic.